

A case of micro-percutaneous nephrolithotomy with macro complication

Mikro-perkütan nefrolitotomi makro komplikasyon

Onur Dede, Mazhar Utangaç, Mansur Dağguli, Namık Kemal Hatipoğlu, Ahmet Ali Sancaktutar, Mehmet Nuri Bodakçı

ABSTRACT

Percutaneous nephrolithotomy is accepted as the standard management approach for kidney stones that are either refractory to extracorporeal shock wave lithotripsy or are >2 cm in diameter. The recently developed micro-percutaneous nephrolithotomy (microperc) technique provides intrarenal access under full vision using an optic instrument with a smaller calibration. A lesser amount of bleeding has been reported with the use of this method. Here we present a case of a bleeding complication on postoperative day 15 after a microperc procedure used to treat a left kidney stone. The complication led to retention of bloody urine in the bladder and required transfusion of 5 units of whole blood.

Key words: Bleeding; complication; micro-PNL.

ÖZET

Perkütan nefrolitotomi (PNL), ekstrakorporeal sok dalga litotripsi'ye (ESWL) dirençli veya 2 cm'den büyük böbrek taşlarının tedavisinde standart tedavi olarak kabul edilmektedir. Minimal bir invazif tedavi olarak kabul edilmesine rağmen kanama ve komşu organ yaralanması gibi ciddi komplikasyonlara da yol açabilir. Son yıllarda geliştirilmiş bir teknik olan Mikroperk yöntemi ile böbreğe tam görüş altında ve daha ince kalibrasyonlu bir optikle giriş sağlanmaktadır. Bu sayede daha az kanama komplikasyonu olabileceği bildirilmiştir. Bu yazıda sol böbrek taşı için mikroperk uyguladığımız bir hastada postop 15. günde ortaya çıkan 5 ünite kan transfüzyonunu gerektiren ve hematogloba yol açan bir kanama komplikasyonunu sunuyoruz.

Anahtar kelimeler: Kanama; komplikasyon; Micro-PNL.

Introduction

Percutaneous nephrolithotomy (PNL) has been recommended as the first-line treatment for kidney stones that are either refractory to extracorporeal shock wave lithotripsy (ESWL) or are >2 cm in diameter according to the guidelines of the European Association of Urology (EAU) and the American Urological Association (AUA). Although it is considered to be a minimally invasive treatment, serious adverse effects such as bleeding and adjacent organ injury have been reported.^[1] The amount of blood loss occurring during PNL has been demonstrated to be directly proportional to the calibration of the instruments used. Therefore, use of instruments with a smaller calibration has been investigated. As a result of these studies, following standard PNL, mini PNL, and

ultra-mini PNL, the micro-percutaneous nephrolithotomy (microperc) technique described by Desai et al.^[2] has been introduced.

Microperc has been designed to approach intrarenal structures and the targeted stone under full visualization of all layers passed through without the need for tract dilation. Although it remains the most innovative technique in use, only a few studies on the application of the microperc technique have been reported. However, the safe use of this technique, even in pediatric cases, has been demonstrated,^[3] and only a scarce number of minimal complications have been reported. Here we present a case of a massive bleeding complication with retention of blood clots in the bladder emerging unexpectedly during postoperative week 3 after microperc.

Department of Urology, Dicle University Faculty of Medicine, Diyarbakır, Turkey

Submitted:
23.04.2014

Accepted:
06.08.2014

Available Online Date:
18.02.2015

Correspondence:
Onur Dede,
Department of Urology, Dicle University Faculty of Medicine, Diyarbakır, Turkey
Phone: +90 505 701 95 30
E-mail: dronurdede@hotmail.com

©Copyright 2015 by Turkish Association of Urology

Available online at
www.turkishjournalofurology.com

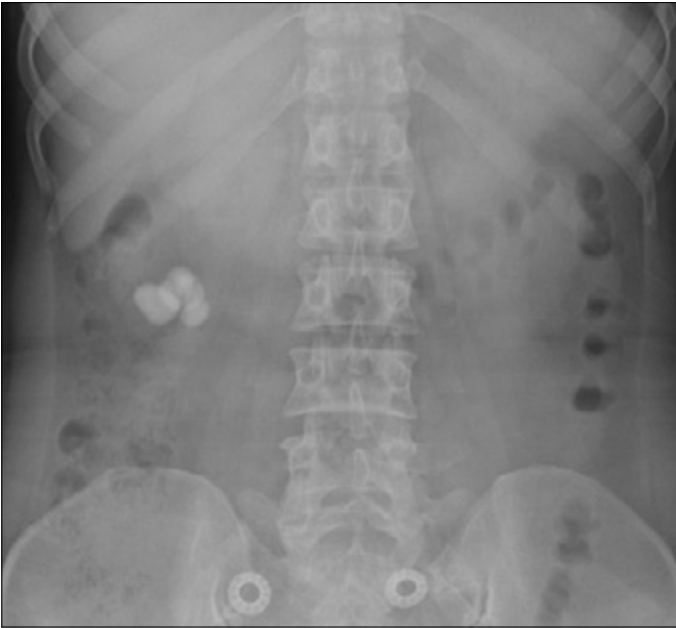


Figure 1. Radiogram (KUB) demonstrated multiple stones in the renal pelvis and lower pole
KUB: kidney-ureter-bladder

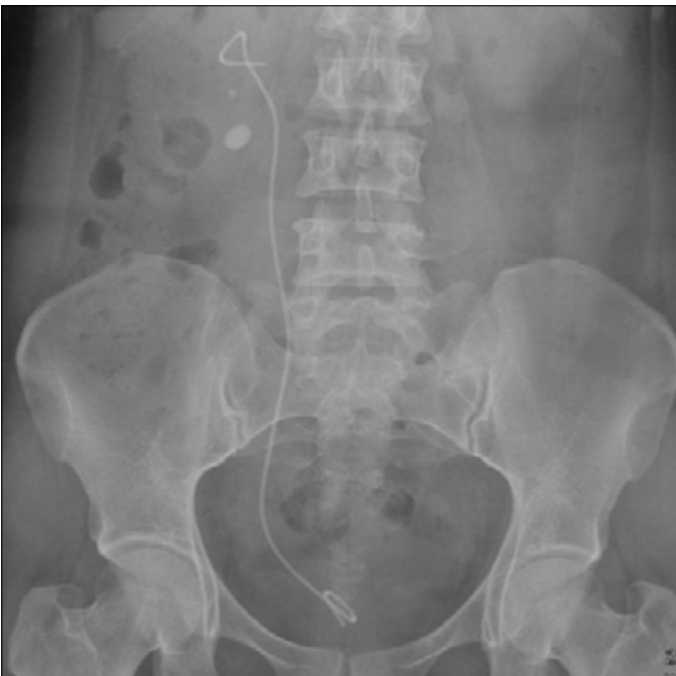

Figure 2. KUB radiogram obtained on postoperative day 1 revealed 2 stones in the lower pole
KUB: kidney-ureter-bladder

Case presentation

A 39-year-old female patient presented to our clinic with right renal colic. Her laboratory test results were as follows: urea 22

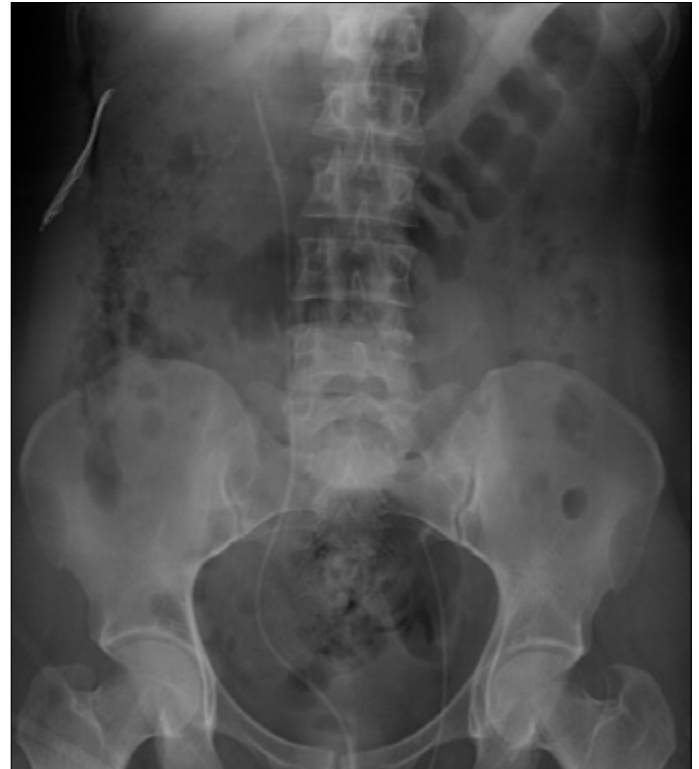

Figure 3. A 5-Fr ureteral catheter was left in the kidney

mg/dL, creatine 1.4 mg/dL, hemoglobin 12.9 mg/dL, leukocyte 7800/mm³. Microscopic examination of the urine did not reveal any evidence of urinary infection. Radiograms kidney ureter bladder (KUB) demonstrated multiple stones in the renal pelvis and lower pole (Figure 1). The total stone burden according to computed tomography (CT) was 900 mm². For right kidney stones, PNL was performed through an intrarenal access directed into the middle calyx. Four renal pelvic stones, each measuring 1 x 1 cm, were extracted. Development of resistant arrhythmia during access into the stones in the lower calyx necessitated premature termination of the procedure following implantation of a double-J stent. KUB radiograms obtained on postoperative day 1 revealed 2 stones in the lower pole (Figure 2). The patient's hemoglobin levels were 12.1 mg/dL.

The patient returned to our clinic 45 days later for removal of the residual stones, and ESWL was recommended. However, the patient declined ESWL after experiencing a panic attack; therefore, we decided to perform a microperc procedure. Her preoperative hemoglobin levels were 12.7 mg/dL. The microperc procedure was performed as described by Desai et al.^[2] using a classical monoplanar access technique. The stones were completely fragmented using a laser probe with a diameter of 256 μ m, and a 5-Fr ureteral catheter was right in situ (Figure 3). The operation and scopy times were 75 and 4 min, respectively. During the procedure, no minor or major vision-

blurring bleeding occurred. The patient's hemoglobin levels were 12.9 mg/dL on postoperative day 1. Because she did not manifest any signs of gross hematuria, her ureteral catheter was removed on postoperative day 1 and she was discharged without any postoperative complication (Figure 4).

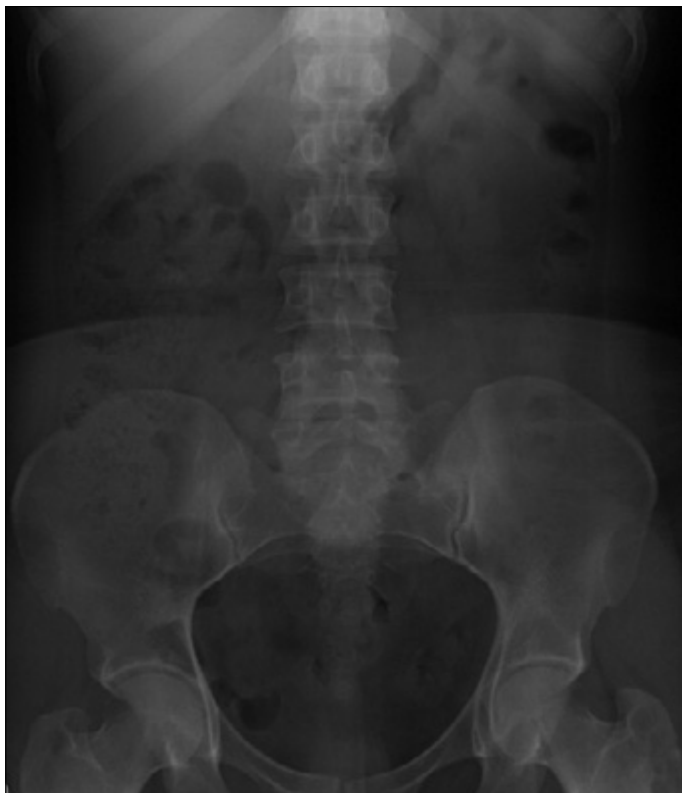

Figure 4. Stones were completely fragmented and removed from the kidney

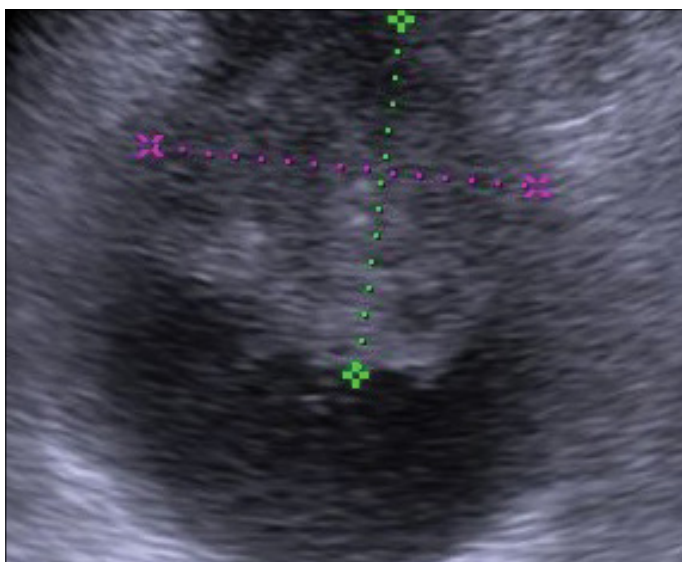


Figure 5. Hematoma in the bladder on ultrasound image

Development of a complication and case management

The patient returned to our clinic on postoperative day 15 with complaints of bloody urine. During medical evaluation, macroscopic hematuria was observed. Her hemoglobin levels was 7.8 mg/dL. Neither perirenal nor renal hematoma were detected by CT. During medical examination, a vesical globe was palpated (Figure 5). The patient was approached conservatively, and 2 units of fresh whole blood were transfused. Her hemoglobin levels increased to 10.3 mg/dL, but decreased gradually during follow-up visits, eventually reaching 7.2 mg/dL. Ultrasonographic (US) examination revealed blood clots and bloody urine completely filling the vesical cavity. A 22-Fr Foley catheter was inserted through the urethra, and the bladder was irrigated with warm water. Two units of whole blood were urgently transfused to the patient. With frequent irrigations lasting for 2 days, the clots were resolved. Superselective renal angiography was planned to clearly identify the bleeding focus (foci), but the patient declined this intervention and was monitored for additional 3 days with an in situ indwelling Foley catheter without hematuria. The next day, she was discharged with a recommendation of bed rest. She did not exhibit any signs of hematuria during follow-up visits at 1, 3, and 6 months.

Discussion

Although it has been considered as an effective and minimally invasive method, complication rates as high as 83% have been reported in various case series.^[4] The most important of these complications is life-threatening bleeding. In a multi-centered study, Unsal et al.^[5] reported that 9.5% of the bleeding episodes required transfusion and that the procedure had to be terminated prematurely in 1.3% of patients because of intractable bleeding. In the literature, bleeding episodes necessitating transfusion have been reported in 0.4%-23% of patients. Stone size, degree of dilation, number of accesses, operation time, and existing comorbidities have been implicated as potential bleeding episode-triggering factors. The degree of dilation and size of the instruments used have been reported to be correlated with the amount of blood loss.^[6] Therefore, creation of smaller access tracts is predicted to cause less parenchymal damage. However, its most important disadvantage is a longer operation time.^[7] Preexisting stones should be fragmented into minute particles so as to extract them through the access sheath or to ensure their passage out of the urinary tract. In the literature, the mean operation time for microperc has been reported to range between 45 and 128 min.^[2,3] In the current case, the operation time was 75 min. Despite this very brief intrarenal access time, our overall operation time appeared to be relatively long. Furthermore, we fragmented the renal stones into very minute particles so as to ensure their easy clearance, which also prolonged the operation time.

To date, only a limited number of studies performed using the microperc technique have been cited in the literature. Safe and effective application of the microperc technique in the management of renal stones in patients of all ages has been demonstrated both in microperc procedures performed by Desai et al.,^[2] who initially described this technique, and in applications of this modality in our country. One of the most striking and important findings from all of the aforementioned publications is that they have not reported any life-threatening complications or adjacent organ injuries.^[3,8] Literature reviews conducted to date revealed that Tepeler et al.^[8] reported intraabdominal fluid extravasation at the end of the operation in an adult patient, which was treated with insertion of a drain. Hatipoğlu et al.^[3] reported postoperative development of diffuse fluid collection within the abdominal cavity in a pediatric patient.

In the limited number of published studies, no massive bleeding complications have been reported, and there have been only minor decreases in hemoglobin levels. In the most recent study performed by Hatipoğlu et al.,^[3] the authors did not report any episode of massive bleeding in the 37 pediatric patients that underwent microperc procedures. From this perspective, the massive bleeding complication encountered in our patient would be the first such case reported in the literature. Because of uneventful access during the perioperative period, as well as the absence of any intraoperative bleeding episode, the late-term hemorrhagic complication on postoperative day 12 was quite an unusual phenomenon.

Percutaneous nephrolithotomy, operation time, nonhydronephrotic kidneys, excess stone burden, intraoperative access time, and use of inappropriately large-sized nephroscopes are among the most important risk factors for massive post-PNL bleeding episodes.^[4] In our case, achievement of a single intrarenal access can be considered as an advantage. The stone burden in the current case was 200 mm², which is within the limits for normal PNL indications. Therefore, nonhydronephrotic kidney was considered as a risk factor for this bleeding complication.

The access needle used in the microperc technique and needles utilized for renal biopsy or percutaneous nephrostomy have nearly identical calibrations. Late-term massive bleeding episodes have been reported following renal biopsy as well as percutaneous nephrostomy procedures. Arteriovenous fistulas or pseudoaneurysms are the most frequently observed etiologic factors for late-term bleeding episodes that lead to persistently lower hematocrit levels.^[9] Selective renal arteriograms, which may reveal the underlying causative factors, are preferred for diagnostic and therapeutic purposes.^[10] However, this procedure was not performed in the current case because the patient was

noncompliant and reluctant to accept this intervention. Selective angiographic examination may also be useful, as is the case with hemorrhage episodes following the microperc procedure. It is an important limiting factor in this case.

Although the microperc method appears to be the most innovative and promising technique among the minimally invasive treatment modalities for renal stones, it can also lead to serious complications. One must be attentive to late-term gross hematuria, which may develop after microperc surgery performed through collecting systems resistant to dilation.

Informed Consent: Written informed consent was obtained from patient who participated in this study.

Peer-review: Externally peer-reviewed.

Author Contributions: Concept - O.D.; Design - O.D., A.A.S.; Supervision - M.N.B.; Funding - N.K.H., O.D.; Materials - M.D.; Data Collection and/or Processing - M.U., M.D.; Analysis and/or Interpretation - O.D., A.A.S.; Literature Review - O.D., M.N.B.; Writer - O.D., A.A.S.; Critical Review - N.K.H., O.D., M.N.B.; Other - M.N.B., N.K.H., M.D.

Conflict of Interest: No conflict of interest was declared by the authors.

Financial Disclosure: The authors declared that this study has received no financial support.

Hasta Onamı: Yazılı hasta onamı bu çalışmaya katılan hastadan alınmıştır.

Hakem değerlendirmesi: Dış bağımsız.

Yazar Katkıları: Fikir - O.D.; Tasarım - O.D., A.A.S.; Denetleme - M.N.B.; Kaynaklar - N.K.H., O.D.; Malzemeler - M.D.; Veri toplanması ve/veya işlemesi - M.U., M.D.; Analiz ve/veya yorum - O.D., A.A.S.; Literatür taraması - O.D., M.N.B.; Yazıyı yazan - O.D., A.A.S.; Eleştirel İnceleme - N.K.H., O.D., M.N.B.; Diğer - M.N.B., N.K.H., M.D.

Çıkar Çatışması: Yazarlar çıkar çatışması bildirmemişlerdir.

Finansal Destek: Yazarlar bu çalışma için finansal destek almadıklarını beyan etmişlerdir.

References

1. Skolarikos A, de la Rosette J. Prevention and treatment of complications following percutaneous nephrolithotomy. *Curr Opin Urol* 2008;18:229-34. [CrossRef]
2. Desai M, Mishra S. 'Microperc' micro percutaneous nephrolithotomy: evidence to practice. *Curr Opin Urol* 2012;22:134-8. [CrossRef]

3. Hatipoglu NK, Sancaktutar AA, Tepeler A, Bodakci MN, Penbegul N, Atar M, et al. Comparison of shockwave lithotripsy and microperc for treatment of kidney stones in children. *J Endourol* 2013;27:1141-6. [\[CrossRef\]](#)
4. Kukreja R, Desai M, Patel S, Bapat S, Desai M. Factors affecting blood loss during percutaneous nephrolithotomy: prospective study. *J Endourol* 2004;18:715-22. [\[CrossRef\]](#)
5. Unsal A, Resorlu B, Atmaca AF, Diri A, Goktug HN, Can CE, et al. Prediction of morbidity and mortality after percutaneous nephrolithotomy by using the Charlson Comorbidity Index. *Urology* 2012;79:55-60. [\[CrossRef\]](#)
6. de la Rosette JJ, Zuazu JR, Tsakiris P, Elsakka AM, Zudaire JJ, Laguna MP, et al. Prognostic factors and percutaneous nephrolithotomy morbidity: a multivariate analysis of a contemporary series using the Clavien classification. *J Urol* 2008;180:2489-93. [\[CrossRef\]](#)
7. Giusti G, Piccinelli A, Taverna G, Benetti A, Pasini L, Corinti M, et al. Miniperc? No, thank you! *Eur Urol* 2007;51:810-5. [\[CrossRef\]](#)
8. Tepeler A, Armagan A, Sancaktutar AA, Silay MS, Penbegul N, Akman T, et al. The role of microperc in the treatment of symptomatic lower pole renal calculi. *J Endourol* 2013;27:13-8. [\[CrossRef\]](#)
9. Xue R, Wang M, Li Q, Zhao XD, Tang XM, Shi JS, et al. Successful interventional treatment of post-biopsy renal artery pseudoaneurysm in pediatric patients. *Clin Nephrol* 2013;79:407-13. [\[CrossRef\]](#)
10. Wang C, Mao Q, Tan F, Shen B. Superselective renal artery embolization in the treatment of renal hemorrhage. *Ir J Med Sci* 2014;183:59-63. [\[CrossRef\]](#)